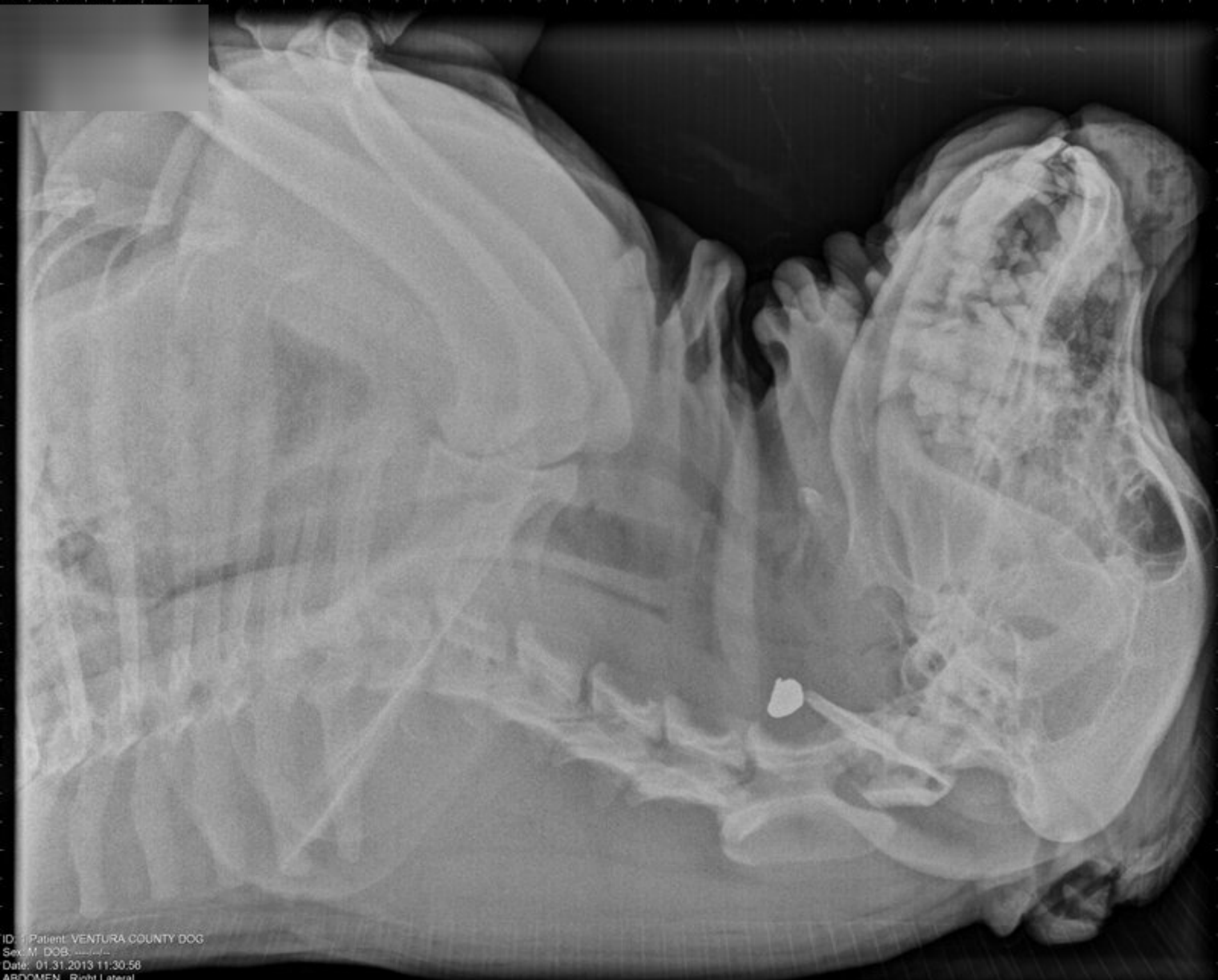
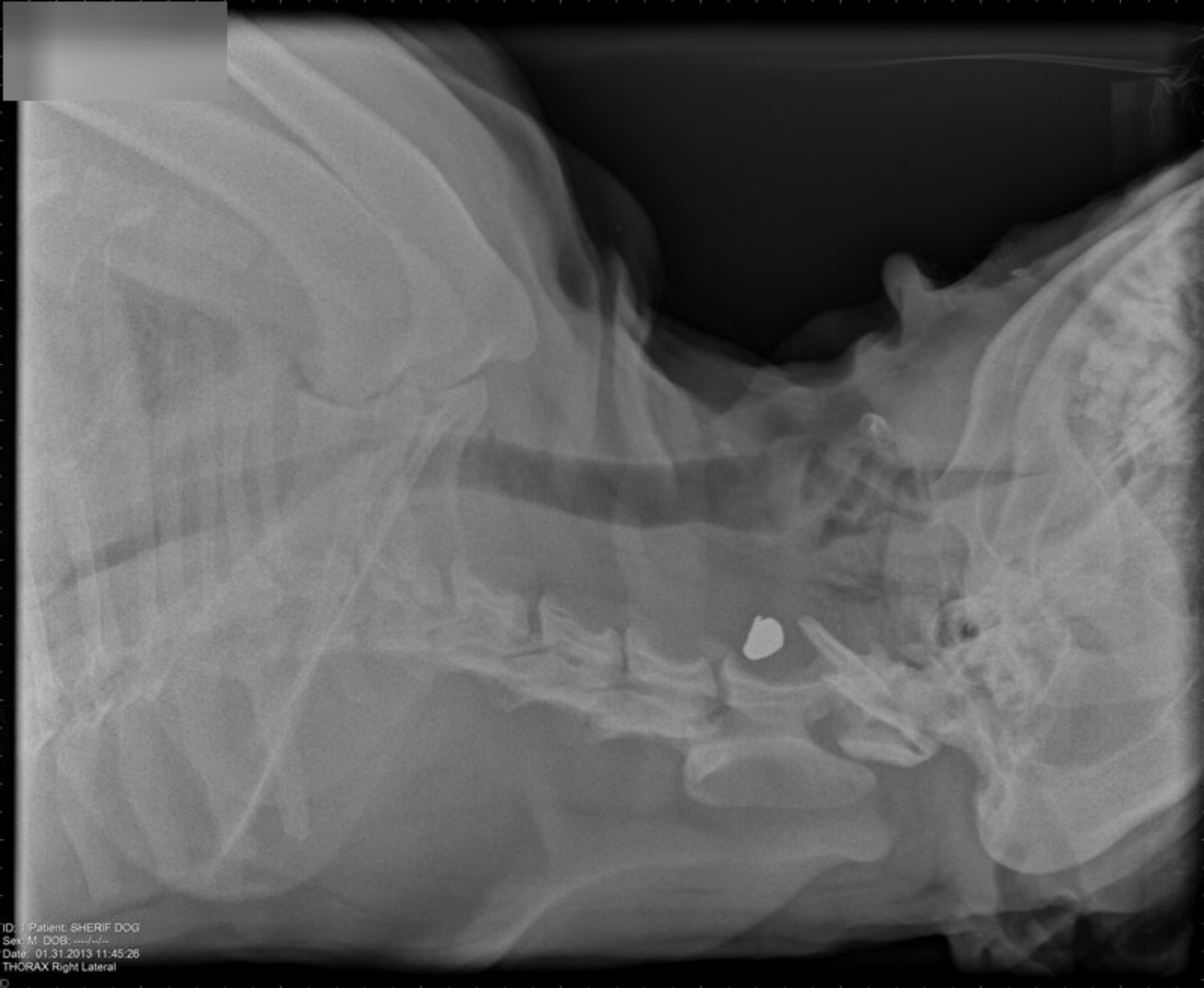


This is a right lateral X-ray of the abdomen. The image shows the thoracic and lumbar spine, the ribs, and the abdominal cavity. The abdominal cavity contains several loops of bowel, which appear as a complex, mottled pattern of soft tissue and gas. The spine is visible as a series of white, rectangular blocks, and the ribs are seen as curved lines extending from the spine. The overall image is in grayscale, typical of medical X-rays.

ID: 1 Patient: SHERIF OOO
Sex: M DOB: ---/---/---
Date: 01.31.2013 11:33:15
ABDOMEN Right Lateral

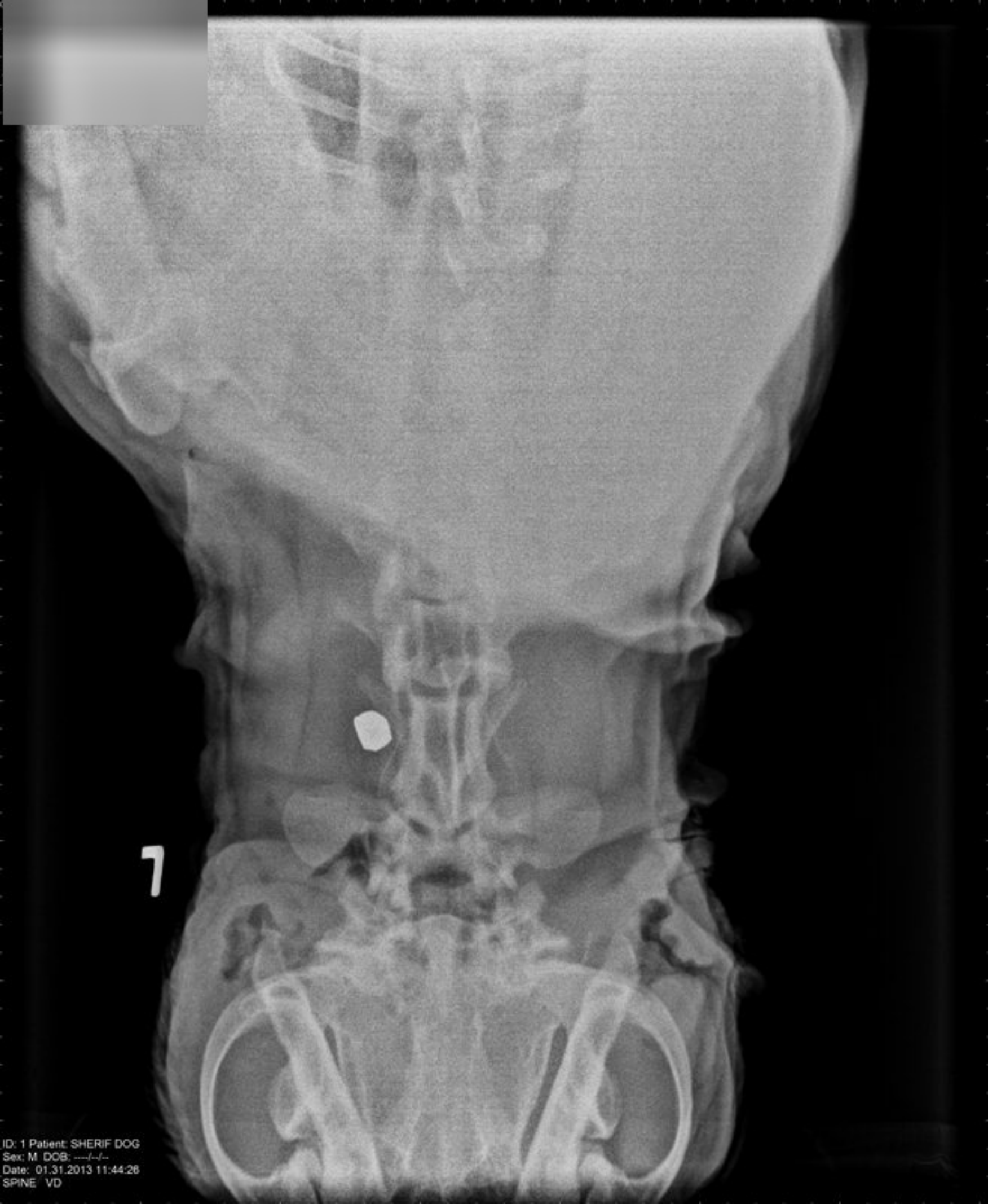

ID: 1 Patient: VENTURA COUNTY DOG
Sex: M DOB: / /
Date: 01.31.2013 11:30:56
ABDOMEN Right Lateral



A lateral radiograph of the thorax. The image shows the vertebral column on the right side, with several thoracic vertebrae clearly visible. The ribs are seen as curved structures extending from the spine. The lung fields are visible on the left side of the image, showing some internal markings. The overall image is in grayscale and has a slightly grainy texture. A small white rectangular artifact is present in the upper right quadrant of the image.

ID: 1 Patient: SHERIF DOG
Sex: M DOB:
Date: 01.31.2013 11:45:28
THORAX Right Lateral



ID: 1 Patient: SHERIF DOG
Sex: M DCB: ---/---
Date: 01.31.2013 11:44:26
SPINE VD